



PATIENT PRESENTING CLINICAL SIGNS

Baby Rinaldi History: Grade III/VI heart murmur. Doing well clinically. Echocardiogram prior to anesthesia for dental prophylaxis. BP: 150-160mmHg.

SPECIES ECHOCARDIOGRAM FINDINGS

Feline 2D, m-mode, color flow and Doppler imaging is available.
BREED **DSH** **Left ventricle:** The LV diameter is normal with adequate myocardial function. The LV wall dimensions are normal. There is a significant fibrosis of the endocardium. False tendon. The endocardium appears mildly remodeled. The papillary muscles appear normal.
SEX **Female Spayed** **Left atrium:** The left atrium is normal. No obvious thrombi or emboli seen.
AGE **15 years** **Mitral valve:** The mitral valve is normal in structure and mobility. No obvious systolic anterior motion is seen.
WEIGHT **7lbs** **Aortic valve/aorta:** The aortic valve is normal in morphology and mobility. Borderline elevated aortic outflow velocity; laminar flow. No aortic insufficiency.
Right ventricle: Normal right ventricular diameter and morphology indicating no overt evidence of pulmonary arterial hypertension.
Right atrium: The right atrium is normal in dimension.
Tricuspid valve: The tricuspid valve appears normal with no tricuspid regurgitation.
Pulmonic valve/pulmonary artery: The pulmonic valve is normal in morphology and mobility. No pulmonic insufficiency. An elevated RVOT velocity is seen on color flow and Spectral doppler.
Pericardium/other: No pericardial or pleural effusion noted. No obvious cardiac masses.
Heart rhythm: ECG reveals a sinus rhythm with an average HR of 200bpm.

INTERPRETED BY

Maggie Machen
Lamy, DVM
DACVIM (Cardiology)

2-Dimensional Measurements

Ao diam (cm)	1.0
LA diam (cm)	1.1
LA:Ao (Swe)	1.1
IVS thickness (cm)	0.42
LVID diastole (cm)	1.2
PW thickness (cm)	0.35
LVID systole (cm)	0.42
FS (%)	66

Doppler Measurements

PV Vmax (m/s)	1.7
AoV Vmax (m/s)	0.9
MR Vmax (m/s)	NA
TR Vmax (m/s)	NA
TR PG (mmHg)	NA

IMAGING PERFORMED BY

Pamela Harrigan,
RDCS

HOSPITAL NAME

Pine Banks Animal
Hospital

INTERPRETATION OF THE FINDINGS

Overtly normal geriatric cardiac structure and function are identified. Significant remodeling fibrosis of the left ventricular wall is noted, which is likely a normal age-related variant; however, follow up is advised. No significant valve leaks are noted, and flow through the aorta is normal in velocity. A dynamic RVOT is noted which is a benign cause of murmurs in cats. No evidence of thyrotoxic cardiomyopathy at this time.

REFERRING VET

Dr. Syed

RECOMMENDATIONS

- Given these findings, no medications are indicated.
- No cardiac contraindication for general anesthesia. Should fluid or steroid therapy be indicated in the future, any senior cat should be monitored for intolerance (changes in RR/RE).
- Monitor at home for signs of cardiac compromise, including respiratory changes and/or signs of a blood clot event (paralysis, neurologic changes).

INVOICE

29988

DATE

4/3/23



PATIENT

Baby Rinaldi

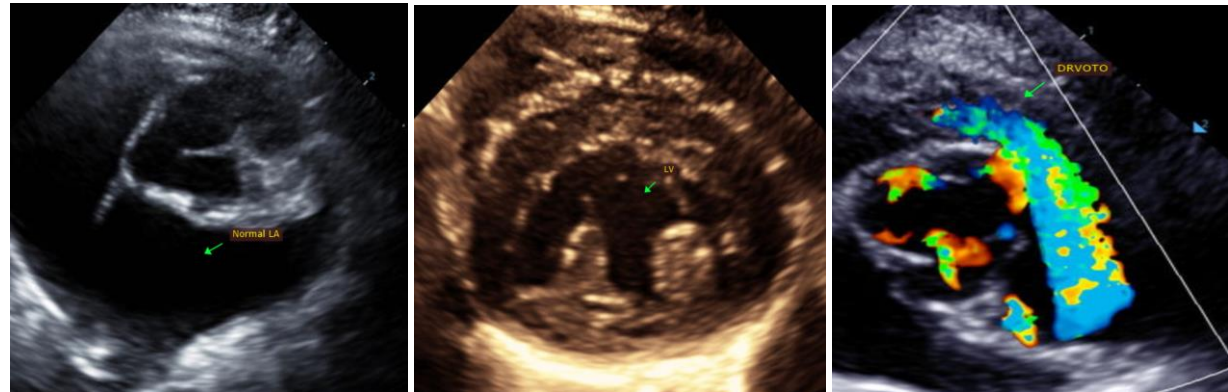
PLAN

- Recommend recheck echocardiogram in 1 year to assess for any progressive issues or development of disease the pre-existing murmur may mask.

SPECIES

Feline

IMAGES



BREED

DSH

SEX

Female Spayed

AGE

15 years

WEIGHT

7lbs

The information and recommendations provided are based on the images presented by the referring veterinarian. No evaluation can be communicated regarding pathology that was not visible in the image/video clips provided.

Thank you for this referral. This report was generated using transcription software, and minor dictation errors may be present. If the clinical or image interpretation does not parallel your findings or if I can be of any further assistance, please contact me.

INTERPRETED BY

Maggie Machen
 Lamy, DVM
 DACVIM (Cardiology)

Maggie Machen Lamy, DVM
Diplomate of the American College of Veterinary Internal Medicine (Cardiology)
 info@sonopath.com

IMAGING PERFORMED BY

Pamela Harrigan,
 RDCS

Echocardiogram performed by: Pamela Harrigan, RDCS
 Pet Animal Ultrasound Service (4paus.com)

HOSPITAL NAME

Pine Banks Animal
 Hospital

REFERRING VET

Dr. Syed

INVOICE

29988

DATE

4/3/23